ijph

Date of Publication - November 2, 2026.

CASE REPORT OPEN ACCESS

INTERNATIONAL JOURNAL OF PUBLIC HEALTH

© 2024 by the authors. This article is an open access article distributed under the terms and conditions of the Creative Commons Attribution (CC BY 4.0) license.

Subcutaneous Facial Emphysema Secondary to Accidental Perforation of Root Canal: A Case Report and Review of Literature.

Abdulaziz Alrashidi[1], Saoud Abdullah Almutairi[1], Abdulaziz Alyahya[1], Mohammed Khashman Almutairi[2], Abdulrahman Mansour Alsulayhim[2], Suhael Ahmed[1]

Author Affiliations

1. *College of Medicine and Dentistry, Riyadh Elm University, Riyadh, Saudi Arabia*
2. *Prince Abdulrahman Advanced Dental Institute*

Abstract

Subcutaneous emphysema is an uncommon but well-documented complication in dental practice characterized by the abnormal presence of air within subcutaneous and fascial tissue planes. It most frequently occurs following the inadvertent introduction of pressurized air into soft tissues during dental procedures, particularly when air-driven handpieces or air syringes are used in close proximity to surgical or traumatized sites. Although often self-limiting, the condition can present with dramatic facial swelling and, in rare instances, may extend into deeper fascial spaces, posing a potential risk to the airway and mediastinum [1,2].

In endodontic and restorative procedures, the use of air to dry operative fields or remove debris may facilitate air entry through pathways created by perforations, open apices, or disrupted cortical bone [3]. Once introduced, air can rapidly dissect along fascial planes, leading to sudden swelling, crepitus on palpation, and in some cases extension to periorbital, cervical, or thoracic regions. The severity of presentation depends on the volume of air introduced and the anatomical pathways available for its spread [4].

Dental procedures involving root canal treatment, post space preparation, and surgical interventions have been frequently implicated in reported cases of subcutaneous emphysema. Iatrogenic perforation of root canals or cortical bone further increases the risk by providing a direct pathway for air infiltration into deeper tissues [5]. Although the condition is often benign and resolves spontaneously with conservative management, early recognition is critical to prevent unnecessary interventions and to monitor for rare but serious complications such as pneumomediastinum or pneumothorax [6].

The present case highlights a rare occurrence of subcutaneous facial emphysema following accidental canal deviation and subsequent use of an air syringe during post space preparation. This report emphasizes the importance of preventive measures, prompt diagnosis, and conservative management in ensuring favorable clinical outcomes.

Introduction

Subcutaneous emphysema is an uncommon but well-documented complication in dental practice characterized by the abnormal presence of air within subcutaneous and fascial tissue planes. It most frequently occurs following the inadvertent introduction of pressurized air into soft tissues during dental procedures, particularly when air-driven handpieces or air syringes are used in close proximity to surgical or traumatized sites. Although often self-limiting, the condition can present with dramatic facial swelling and, in rare instances, may extend into deeper fascial spaces, posing a potential risk to the airway and mediastinum [1,2].

In endodontic and restorative procedures, the use of air to dry operative fields or remove debris may facilitate air entry through pathways created by perforations, open apices, or disrupted cortical bone [3]. Once introduced, air can rapidly dissect along fascial planes, leading to sudden swelling, crepitus on palpation, and in some cases extension to periorbital, cervical, or thoracic regions. The severity of presentation depends on the volume of air introduced and the anatomical pathways available for its spread [4].

Dental procedures involving root canal treatment, post space preparation, and surgical interventions have been frequently implicated in reported cases of subcutaneous emphysema. Iatrogenic perforation of root canals or cortical bone further increases the risk by providing a direct pathway for air infiltration into deeper tissues [5]. Although the condition is often benign and resolves spontaneously with conservative management, early recognition is critical to prevent unnecessary interventions and to monitor for rare but serious complications such as pneumomediastinum or pneumothorax [6].

The present case highlights a rare occurrence of subcutaneous facial emphysema following accidental canal deviation and subsequent use of an air syringe during post space preparation. This report emphasizes the importance of preventive measures, prompt diagnosis, and conservative management in ensuring favorable clinical outcomes.

Case Presentation

A 20-year-old female patient, medically fit and classified as ASA I according to the American Society of Anesthesiologists Physical Status Classification System, presented to the Prosthodontics Department for evaluation and management requiring post and core restoration of the maxillary right central incisor (tooth #11). The patient had a history of prior endodontic intervention following an episode of acute dental pain,

initially managed at a primary healthcare center. At that time, emergency treatment in the form of a pulpotomy was performed, and the tooth was subsequently restored with a temporary restoration.

Upon presentation, a comprehensive clinical and radiographic assessment was carried out. Clinically, the maxillary right central incisor was structurally compromised and deemed unsuitable for definitive restoration without reinforcement. The tooth required post and core buildup to achieve adequate retention and resistance form for the planned final prosthetic rehabilitation. Radiographic examination revealed a periapical radiolucency localized to the mesial aspect of the root, suggestive of persistent periapical pathology, likely secondary to previous pulpal infection and unresolved inflammatory changes.

Following thorough evaluation, clinical findings and radiographic evidence were correlated to establish a working diagnosis. The prognosis of the tooth was considered guarded but favorable for rehabilitation with appropriate endodontic and prosthodontic management. A comprehensive treatment plan was formulated, including post space preparation, post and core placement, and definitive crown restoration. The rationale, procedural steps, potential risks, benefits, and alternative treatment options were explained in detail to the patient, and informed consent was obtained prior to initiating treatment.

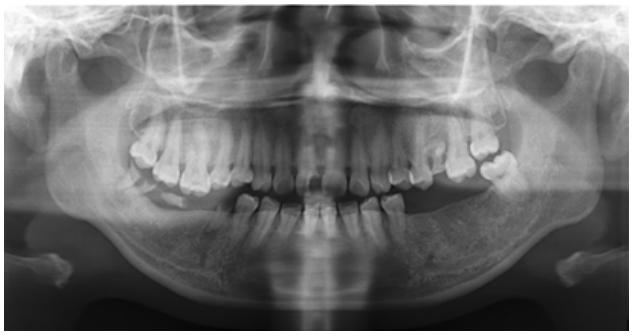

IMAGE 1

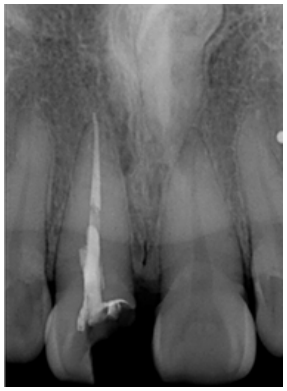

IMAGE 2



IMAGE 3

Procedure

Root canal preparation for post space was initiated on tooth #11 (Image 1). During the procedure, an intraoperative radiograph was taken, which revealed a deviation in the canal preparation, likely caused by bur misdirection (Image 2). At this stage, clinically, only slight localized swelling was observed in the adjacent buccal mucosa.

An air syringe was subsequently used to clear debris from the operative field. Within seconds of air application, a sudden and noticeable intraoral swelling developed in the buccal mucosa adjacent to the right maxillary central incisor. This was rapidly followed by marked extraoral swelling involving the right midfacial region (Image 3), consistent with the spread of air through facial tissue planes.

Diagnosis

Based on the rapid onset of swelling immediately following air syringe use, associated crepitus on palpation, and spread through facial planes, a diagnosis of subcutaneous facial emphysema secondary to accidental perforation during root canal instrumentation was established.

Management

The patient was immediately reassured and closely monitored. Conservative management was adopted, as there were no signs of airway compromise, systemic involvement, or infection. The treatment included:

- Discontinuation of air-driven instruments
- Close observation of swelling progression
- Analgesics for discomfort (as needed)
- Prophylactic antibiotics to reduce risk of secondary infection
- Patient instructions to avoid activities increasing intraoral pressure (e.g., blowing, sneezing with closed mouth, or straining)

No surgical intervention was required.

Clinical Course and Outcome

Following initial management, the swelling transiently increased and extended to the circumorbital region within the first 24 hours. Despite this extension, the patient remained systemically stable, and no respiratory or neurological symptoms were reported.

From the second day onward, gradual spontaneous resolution of swelling was observed. By the fifth day, the facial swelling had completely subsided with no residual crepitus or functional limitation.

Follow-Up

The patient was reviewed after one week and again at subsequent follow-ups. Healing was uneventful, with complete resolution of symptoms and no complications such as infection, fibrosis, or recurrence of emphysema. Endodontic management was planned to be completed after full stabilization of the soft tissues.

Review of literature

Pathophysiology

Subcutaneous emphysema associated with endodontic procedures occurs when pressurized air is inadvertently introduced into the root canal system and forced beyond the confines of the tooth into surrounding tissues. This typically happens during the use of an air syringe in an open canal, particularly when the natural apical seal is compromised or when an iatrogenic perforation is present. Under pressure, air overcomes the resistance of periapical tissues and gains access to adjacent soft tissue spaces [5].

The mechanism can be summarized as follows:

- Direct introduction of pressurized air into the root canal during drying or debris removal
- Escape pathways for air include:
  - The apical foramen, especially in cases of over-instrumentation
  - Lateral or accessory canals, which provide additional channels of communication

    - Iatrogenic perforations, creating an abnormal pathway into periodontal or periapical tissues
- Dissection through loose connective tissue, where air travels rapidly along planes of least resistance

Once air enters the soft tissues, it accumulates in the form of multiple small pockets, leading to characteristic clinical features:

- Diffuse swelling with rapid onset
- Palpable crepitus, caused by air bubbles within the tissue
- Possible vascular compression, which may result in mild blanching or a feeling of tightness

Unlike fluid extrusions, which spread slowly and are often confined, pressurized air can disseminate quickly due to its ability to separate tissue planes. The interconnected nature of fascial spaces in the head and neck further facilitates this spread [6].

Air may extend beyond the initial site along anatomical pathways, including:

- The periorbital region, leading to eyelid swelling and possible eye closure
- The parapharyngeal and masticatory spaces, which can affect swallowing and jaw movement
- The cervical fascial planes, with potential downward spread
- The mediastinum (in rare but serious cases), resulting in pneumomediastinum, which may compromise respiratory or cardiovascular function

The extent and speed of air dissemination depend on factors such as the pressure applied, the size and location of the pathway (e.g., perforation), and the nature of surrounding connective tissues. Understanding this mechanism is essential for both prevention and early recognition of this complication [7].

Diagnosis

The diagnosis of subcutaneous emphysema during endodontic treatment is largely clinical and time-sensitive, relying on recognition of its characteristic presentation. It is typically suspected when an abrupt swelling occurs during or immediately after the procedure, especially following the use of compressed air or instrumentation that may have created a pathway for air entry. The rapid onset and progression of swelling distinguish it from most other causes of facial enlargement in dental settings [8].

Key diagnostic features include:

- Sudden onset swelling developing within seconds to minutes during the procedure
- Diffuse, soft, and non-tender enlargement of the affected area, often without significant redness in early stages
- Palpable crepitus, a crackling or popping sensation on gentle palpation, which is highly characteristic and indicates the presence of air within soft tissues
- Possible extension of swelling to adjacent regions such as the periorbital or cervical areas

Imaging can be used to support the clinical diagnosis and assess the extent of involvement:

- Conventional radiographs may reveal radiolucent streaks or small air pockets, although findings can be subtle
- Computed tomography (CT) is more sensitive and can clearly demonstrate the presence and spread of air within fascial spaces, particularly in extensive or atypical cases

A careful differential diagnosis is essential to rule out other causes of facial swelling:

- Allergic reaction: typically presents with rapid swelling but is often associated with itching, erythema, or urticaria, and importantly does not exhibit crepitus
- Hematoma: usually follows vascular injury, develops more gradually, may show discoloration, and lacks the crackling sensation on palpation
- Infection (cellulitis or abscess): generally has a delayed onset, is associated with pain, redness, and may include systemic signs such as fever or malaise

Accurate diagnosis depends on correlating the timing of onset, clinical examination findings (especially crepitus), and procedural history, allowing prompt differentiation from other conditions and appropriate management.

Management and Treatment

The management of subcutaneous emphysema following endodontic procedures depends on the extent of air spread and severity of symptoms, but in most cases it is conservative and focused on preventing complications while allowing spontaneous resolution. Early recognition and prompt intervention are essential to avoid progression into deeper fascial spaces.

Immediate management should be initiated as soon as the condition is suspected. This includes:

- Immediate termination of the procedure to prevent further air entry
- Reassurance of the patient, as the sudden swelling can be alarming despite being usually self-limiting
- Careful monitoring of airway, breathing, and vital signs, especially in the early phase when swelling may still be progressing

Pharmacological therapy is primarily preventive and symptomatic:

- Broad-spectrum antibiotics (such as amoxicillin) are commonly prescribed to reduce the risk of secondary infection, since introduced air may carry oral microorganisms into deeper tissues
- Analgesics or NSAIDs are given to manage discomfort, although pain is typically mild

Supportive care plays an important role in limiting the spread and promoting resolution:

- Cold compresses are recommended during the first 24 hours to minimize further diffusion of air
- Patients should be instructed to avoid activities that increase intraoral or sinus pressure, such as nose blowing, forceful coughing, sneezing, or using straws, as these can exacerbate the condition

In **advanced or complicated** cases, more intensive management may be required. Hospitalization should be considered if:

- The emphysema extends into the cervical region or mediastinum
- The patient develops respiratory symptoms, dysphagia, or voice changes
- There is concern for airway compromise

Such cases may require:

- Close inpatient monitoring
- Intravenous antibiotics

Additional imaging to assess the extent of air spread

Outcome

The prognosis of subcutaneous emphysema following endodontic procedures is generally favorable, particularly when the condition is recognized early and managed conservatively. In most reported cases, the

introduced air is gradually absorbed by the surrounding soft tissues without the need for invasive intervention. The clinical course typically follows a self-limiting pattern, with a noticeable reduction in swelling over the first few days [8].

Key points regarding outcome include:

- Spontaneous resolution usually occurs within 3–10 days as the entrapped air is gradually resorbed
- Complete clinical recovery is commonly observed within 1–2 weeks
- No long-term sequelae are expected in uncomplicated cases when appropriate precautions and monitoring are followed
- Resolution is often progressive, beginning with reduction in facial swelling followed by disappearance of crepitus

The overall prognosis remains excellent, provided that there is no progression into deeper fascial spaces or development of secondary infection. Severe complications such as mediastinal involvement are rare but may prolong recovery and require closer medical supervision [9].

Clinical Significance

This case underscores several important clinical lessons relevant to routine endodontic practice. Although subcutaneous emphysema is uncommon, it can occur suddenly and dramatically, even during seemingly minor procedural steps such as drying the canal.

Key clinical implications include:

- Even brief use of an air syringe in an open or compromised canal can introduce sufficient pressure to cause extensive emphysema
- The maxillary anterior region is particularly susceptible due to its thin cortical bone and direct communication with facial fascial spaces, allowing rapid spread of air
- Awareness of this complication is essential for early recognition and prevention of unnecessary investigations or misdiagnosis

From a preventive standpoint, strict adherence to safe clinical protocols is crucial:

- Avoid using compressed air in open root canals, especially when perforation or apical communication is suspected
- Prefer paper points for canal drying, which are safe and effective
- Use gentle suction or low-pressure techniques for debris removal instead of air syringes [10,11]

Overall, this case reinforces that prevention is the most effective strategy, and careful attention to technique can significantly reduce the risk of this potentially alarming but avoidable complication.

Conclusion

This case highlights the risk of subcutaneous emphysema as a rare but potentially alarming complication of endodontic procedures, particularly following the use of pressurized air in cases of inadvertent canal or cortical perforation. Prompt recognition, immediate cessation of air usage, and conservative management typically result in favorable outcomes, as demonstrated in this case. Subcutaneous facial emphysema is a rare but potentially alarming complication of endodontic procedures that can occur following the inadvertent introduction of pressurized air into the root canal system, particularly in the presence of apical communication or iatrogenic perforation. The condition is characterized by the sudden onset of swelling and the presence of crepitus, with rapid dissemination of air along fascial planes of the head and neck region. Although the clinical presentation may appear dramatic, the condition is typically self-limiting and resolves completely with conservative management in most cases.

References

1. Sarfi D, Haitami S, Farouk M, Yahya IB. Subcutaneous emphysema during mandibular wisdom tooth extraction: Cases series. Annals of medicine and surgery. 2021 Dec 1;72:103039.
2. Shimizu R, Sukegawa S, Sukegawa Y, Hasegawa K, Ono S, Fujimura A, Yamamoto I, Ibaragi S, Sasaki A, Furuki Y. Subcutaneous emphysema related to dental treatment: a case series. InHealthcare 2022 Feb 1 (Vol. 10, No. 2, p. 290). MDPI.
3. Tüfenkçi P, Yılmaz K, Adigüzel M. Effects of the endodontic access cavity on apical debris extrusion during root canal preparation using different single-file systems. Restorative Dentistry & Endodontics. 2020 Jun 4;45(3).
4. McKenzie WS, Rosenberg M. Iatrogenic subcutaneous emphysema of dental and surgical origin: a literature review. Journal of Oral and Maxillofacial Surgery. 2009 Jun 1;67(6):1265-8.
5. Mishra L, Patnaik S, Patro S, Debnath N, Mishra S. Iatrogenic subcutaneous emphysema of endodontic origin–case report with literature review. Journal of clinical and diagnostic research: JCDR. 2014 Jan 12;8(1):279.
6. Hülsmann M, Hahn W. Complications during root canal irrigation–literature review and case reports. International endodontic journal. 2000 May 1;33(3).

7. Busuladzic A, Patry M, Fradet L, Turgeon V, Bussieres M. Cervicofacial and mediastinal emphysema following minor dental procedure: a case report and review of the literature. Journal of Otolaryngology-Head & Neck Surgery. 2020 Jan;49(1):61.
8. Sahin AG, Kurtis MB. Subcutaneous Emphysema Following Periodontal Interventions: A Comprehensive Literature Review and Clinical Considerations. Dentistry Journal. 2026 Mar 11;14(3):163.
9. Battrum DE, Gutmann JL. Implications, prevention and management of subcutaneous emphysema during endodontic treatment. Dental Traumatology. 1995 Jun;11(3):109-14.
10. Fasoulas A, Boutsioukis C, Lambrianidis T. Subcutaneous emphysema in patients undergoing root canal treatment: a systematic review of the factors affecting its development and management. International Endodontic Journal. 2019 Nov;52(11):1586-604.
11. Jones A, Stagnell S, Renton T, Aggarwal VR, Moore R. Causes of subcutaneous emphysema following dental procedures: a systematic review of cases 1993-2020. British dental journal. 2021 Oct 22;231(8):493-500.